

HAART AND THE LIVER: FRIEND OR FOE?

J. A. Pineda, J. Macías, J. A. Mira, N. Merchante, J. del Valle, K. I. Neukam

Unit of Infectious Diseases, Hospital Universitario de Valme, Seville, Spain

Abstract

The overall effect of HAART on the liver is the result of the balance between hepatotoxicity and the consequences of immunoreconstitution on the evolution of HIV-associated liver diseases, particularly viral hepatitis. HAART may lead to the emergence of acute toxic hepatitis, steatosis, steatohepatitis, liver fibrosis, and noncirrhotic portal hypertension. On the other hand, HAART use has been associated with slower fibrosis progression in HIV/HCV-coinfected patients in most studies dealing with this issue. As well, an improvement of the clinical outcome of liver disease has been reported in patients taking HAART. For these reasons, the short- and mid-term effects of HAART on the liver are mostly beneficial.

INTRODUCTION

It is well-known that HIV-coinfection accelerates the progression of hepatitis C virus (HCV)-related liver disease. In fact, while some studies have yielded discordant results, most reports and two metaanalyses of nine (Graham CS 2001) and 29 studies (Deng L 2009), respectively, have proven a strong association between HIV-coinfection and an increased risk for cirrhosis, end-stage liver disease and death. This effect of HIV on liver disease progression is clearly related with immunosuppression. Thus, in cross-sectional studies based on single liver biopsies, patients with lower CD4 cell counts present more advanced stages of fibrosis (Benhamou Y 1999, Macías J 2004, Martín Carbonero L 2004). Likewise, patients with deeper immunosuppression have poorer clinical outcomes than those with higher CD4 counts (Qurishi N 2003, Merchante N 2006).

The underlying mechanism of the effect of HIV infection on the progression of HCV-related liver disease is not completely understood. A study, carried out in hepatoma cell lines, have shown that HIV and the surface protein gp120 increase HCV replication and enhance the expression of TGF β 1, a major mediator in fibrogenesis. This effect is blocked by antibodies against co-receptors CCR5 and CXCR4, as well as using a neutralizing antibody against TGF β 1, indicating that the action of HIV on HCV replication depends on TGF β 1 (Lin W 2008). These findings suggest that HIV not only increases the replication of HCV, but also contributes to fibrosis progression. However, in another study, intrahepatic mRNA levels of inflammatory cytokines were significantly higher in HIV-posi-

tive than in HIV-negative patients harboring hepatitis C, whereas mRNA levels of profibrogenic cytokines did not differ between the two groups. These facts support that the accelerated liver disease progression in HIV/HCV-coinfected patients might reflect enhanced intrahepatic inflammatory responses rather than increased local transcription of directly profibrogenic cytokines (Kuntzen T 2008). Finally, results reported by our group showed that HIV coinfection increases the expression of Fas receptors in hepatocytes of HCV carriers, indicating that hepatocyte apoptosis is enhanced in these patients (Macías J 2005).

Highly active antiretroviral therapy (HAART) leads to reconstitution of the immune system, which may improve the control of HCV infection and slow down the subsequent fibrogenesis. However, antiretroviral drugs may also cause several hepatic disorders in the short and long-term, some of them still not well-known. Because of this, HAART might be either a friend or rather a foe for the liver in HIV/HCV-coinfected patients. Overall, the effect of HAART on the liver will be the result of the balance between the effects of immune reconstitution and those of liver toxicity. In the following lines, the toxicity of HAART, as well as the benefits of this therapy, are analyzed.

LIVER DAMAGE ASSOCIATED WITH HAART

All antiretroviral drugs may lead to the emergence of acute toxic hepatitis. However, most cases of acute toxic hepatitis are subclinical and spontaneously subside. These episodes of self-limited hypertransaminasemia do not seem to enhance the progression of HCV-related liver disease. Thus, in a study of 116 HIV/HCV-coinfected patients with liver biopsy and previous follow-up, patients with advanced fibrosis did not show peak elevations of ALT more commonly than subjects without advanced fibrosis (Vergara S 2007).

Many issues regarding liver damage associated with HAART in the long-term are still far from clear. Liver steatosis is common in HIV/HCV-coinfected patients under antiretroviral therapy. Some degree of steatosis is found in up to 70% of liver biopsies from HIV/HCV-coinfected patients, with percentages of patients showing steatosis in more than 30% of hepatocytes which range from 2-11% (McGovern B 2006, Neau 2007). The factors associated with the presence of steatosis in this population, particularly the role of antiretroviral drugs, are a matter of controversy. It has

been reported that ritonavir treated mice have an increase of the active form of sterol regulatory element-binding protein (SREBP)-1c in liver cells, which leads to an increased lipogenesis. In addition, protease inhibitors also slow down the intracellular degradation of APO-B-100, prompting an overproduction of VLDL particles. Finally, these drugs may inhibit the LDL receptor-related protein, reducing the clearance of VLDL from circulation (Mooser V 2001). These facts support that protease inhibitors might promote the emergence of liver steatosis. However, no study based on liver biopsy has revealed to date an independent association between treatment with protease inhibitors and the presence of steatosis. Conversely, the use of dideoxynucleosides, particularly d4T, has been found to be an independent predictor of liver steatosis in several studies (McGovern B 2006, Pascual-Pareja JF 2009, Sulkowski 2005). Dideoxynucleosides have a high potential for mitochondrial toxicity, which causes defective beta-oxidation of free fatty acids. Since steatosis promotes the progression of fibrosis, it is conceivable that HIV/HCV-coinfected patients receiving drugs inducing steatogenesis will develop with time more severe liver fibrosis.

HIV-infected patients on HAART show higher levels of insulin resistance than those without therapy and healthy controls. This disorder is mainly associated with treatment with protease inhibitors (Brown TT 2005). Insulin resistance prompts fibrosis progression in HCV-monoinfected patients. In HIV/HCV-coinfection, a recent study has shown that patients with higher levels of insulin resistance, as measured by the HOMA method, harbor greater levels of liver stiffness, a reliable marker of fibrosis (Merchante N 2009). This finding supports that insulin resistance is also a cofactor for fibrosis progression in the setting of HIV/HCV coinfection and also provides a rationale to think that HAART might eventually lead to more severe fibrosis stages.

In the few last years, an increasing number of cases of noncirrhotic portal hypertension, observed in HIV-infected patients without hepatitis coinfection, have been reported (Maida I 2006, Schiano D 2007, Mallet V 2007). The underlying liver injury has been nodular regenerative hyperplasia in some of these cases (Mallet V 2007, Maida I 2008) and hepatoportal sclerosis (Schiano TD 2007) in others. This disorder is believed to be associated with long-term exposure to didanosine (Maida I 2006, Mallet V 2007) and it seems to improve with the removal of such a drug (Maida I 2008). These data suggest that some antiretroviral drugs may cause unexpected liver diseases after years of exposure. Fortunately, these cases seem to be uncommon. To gain additional knowledge on this topic, we have screened 258 HIV-infected patients, without HCV or HBV coinfection, for the presence of liver stiffness equal to or higher than 7.2 KPa by transient elastometry. Twenty-nine (11%) subjects showed abnormal liver stiffness, according to this threshold. Fifteen of them accepted to undergo a liver biopsy and all of them, but one, had some degree of liver injury (Fig. 1). The most common diagnoses after biopsy were alcoholic liver disease and fibrosis of unknown origin, which reached the stage of cirrhosis in one pa-

tient. Factors independently associated with liver stiffness equal to or above 7.2 KPa in the multivariate analysis were: prior exposure to didanosine, exposure to abacavir, a daily alcohol intake ≥ 50 g/day, age older than 40 years and a CD4 cell count equal to or lower than 200/mm³. Specifically, the longer the exposure to didanosine, the higher the liver stiffness. These results reinforce the hypothesis that some antiretroviral drugs, like didanosine, may cause liver damage with long-term exposure.

BENEFITS OF HAART ON THE LIVER IN HIV/HCV COINFECTION

Besides the above-stated potential for liver damage, HAART seems to yield clear benefits to the progres-

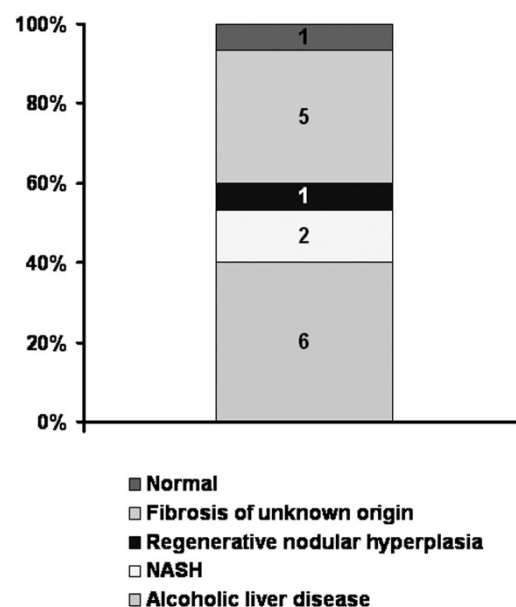


Fig. 1. Diagnosis in HIV-infected patients without HCV or HBV coinfection, showing liver stiffness ≥ 7.2 KPa, and who underwent liver biopsy (n = 15).

sion of HCV-related liver disease in the short and mid-term. Indeed, HAART induces recovery of HCV-specific T-cell response to HCV core protein, which parallels with a decline in plasma HCV-RNA load in HIV/HCV-coinfected patients (Rohrbach J 2009). This immunological effect correlates with the findings observed in histological and clinical studies. Thus, studies analyzing single biopsies have shown that less severe liver fibrosis is associated with either HAART (Verma S 2006) or the consequences of a correct HAART, i. e., higher CD4 cell count (Benhamou Y 1999, Macías J 2004, Martín-Carbonero L 2004) and undetectable plasma HIV-RNA load (Bräu N 2006).

Longitudinal studies have provided conflicting results about the effect of HAART on the progression of liver fibrosis. Thus, a study based on paired biopsies taken from 174 patients belonging to the cohort of the Johns Hopkins University showed no association between HAART and changes in the fibrosis stage (Sulkowski 2007). Moreover, a recent study, in which APRI was sequentially measured, showed that HAART

Table 1. Factors associated with progression 1 or more stages between two paired liver biopsies in 135 patients from Spain in the multivariate study.

Parameter	Categories	RR (95% CI)	p
Undetectable HIV viremia ¹	Yes vs. No	0.61 (0.39-0.93)	0.03
Baseline necroinflammatory activity	L2-3 vs. L0-1	1.77 (1.16-2.7)	0.009
Time between liver biopsies	Per 1 year increase	1.11 (1.03-1.2)	0.01
Response to anti-HCV treatment	ETR vs. no ETR	0.41 (0.19-0.88)	0.02

¹Undetectable HIV RNA in $\geq 70\%$ determinations during the follow-up.

RR (95% CI): Relative risk (95% confidence interval);

ETR: End of treatment response.

is associated with increasing values of this index over time in HIV/HCV co-infected patients. According to the opinion of the authors, this finding would suggest that patients might be experiencing cumulative hepatotoxicity from antiretrovirals (Moodie EEM 2009). To further clarify this topic, we have studied paired biopsies from 135 HIV/HCV-coinfected patients studied in nine hospitals in Spain. The median time between biopsies was 3.3 years. Overall, 44% of patients progressed at least one fibrosis stage of the Scheuer's scoring system, including 56% of those who showed F0 or F1 at the initial biopsy. The factors independently associated with lack of fibrosis progression were low necroinflammatory activity at the first biopsy, longer time from the baseline to the final sample, response to HCV therapy and undetectable plasma HIV-RNA between biopsies (Table 1). The latter results show that a correct HAART slow down HCV-related fibrosis progression in HIV-coinfected patients.

Researchers which have assessed the clinical outcome in patients with HIV/HCV coinfection have uniformly found results consistent with the histological benefit observed in the above-mentioned study. Thus, in the Bonn and in the San Francisco cohorts, HAART was associated with a lower liver related mortality (Qurishi N 2003, Bonacini M 2004). This beneficial effect has also been reported even in the most advanced stages of liver disease (Merchante N 2006). Accordingly, a greater increase of CD4 cell count after starting HAART has been found to be associated with a reduced incidence of liver decompensation and a longer survival (Pineda JA 2007).

Studies appraising the impact of specific antiretroviral drugs on liver fibrosis progression have yielded conflicting results. In fact, whereas some studies have reported that the rate of fibrosis progression in patients taking protease inhibitors is slower than in those receiving nevirapine (Macías J 2004), other studies have found the opposite results (Berenguer J 2008) or no association at all between specific drugs and fibrosis progression (Martin-Carbonero 2004, Verma S 2006). However, all these are retrospective studies and inherent biases likely explain the controversial results. This topic will remain unclear, unless a specific randomized clinical trial to assess it is undertaken.

The beneficial effect of HAART on the progression of HCV infection has made the outcome of liver disease in HIV/HCV-coinfected patients more similar

to that of HCV-monoinfected subjects than it used to be before the HAART era. However, HIV still negatively affects the progression of liver disease in HCV carriers. Thus, a recent metaanalysis, where studies carried out in patients with and without HAART were analyzed separately, found that the course of HCV infection continues to be worse in HCV/HIV-coinfected patients taking HAART. However the risk ratio for cirrhosis between coinfecting and HCV-monoinfected patients has declined from 2.49 in patients without HAART to 1.72 in those receiving HAART (Thein H 2008).

CONCLUSIONS

There are data showing that the use of HAART is associated with several sorts of liver injuries. This fact is certainly a threat of an increased rate of serious liver disorders in the setting of HIV/HCV-coinfected patients. However, the effects of HAART on liver fibrosis progression in these patients are clearly beneficial, at least in the short and mid-term. The use of HAART is likely one of the reasons why the mortality due to liver disease has stopped increasing among HIV-infected patients seen in places where HCV-coinfection is a major problem (del Valle J 2008, Núñez-Fernández C 2009). Because of this, the effects of HAART on the progression of HCV-related liver disease in coinfecting patients largely outweigh the potential risks for long-term toxicity. Accordingly, an earlier starting of ART in patients with HIV/HCV-coinfection is sufficiently justified.

REFERENCES

- Benhamou Y, Bochet M, Di Martino V, et al. Liver fibrosis progression in human immunodeficiency virus and hepatitis C virus coinfecting patients. *Hepatology* 1999; 30: 1054-1058.
- Berenguer J, Bellón JM, Miralles P, et al. Association between exposure to nevirapine and reduced liver fibrosis progression in patients with HIV and hepatitis C virus coinfection. *Clin Infect Dis* 2008; 46: 137-143.
- Bonacini M, Louie S, Bzowej N, Wohl AR. Survival in patients with HIV infection and viral hepatitis B or C: A cohort study. *AIDS* 2004; 18: 2039-2045.
- Bräu N, Salvatore M, Ríos-Bedoya CF, et al. Slower fibrosis progression in HIV/HCV-coinfected patients with successful HIV suppression using antiretroviral therapy. *J Hepatol* 2006; 44: 47-55

- Brown TT, Li X, Cole SR, Kingsley LA, et al. Cumulative exposure to nucleoside analogue reverse transcriptase inhibitors is associated with insulin resistance markers in the Multicenter AIDS Cohort Study. *AIDS* 2005; 19: 1375-1383.
- del Valle J, Macías J, Mira JA, et al. Changes in liver-related hospital admissions and hospital mortality among HIV-infected patients (1998 to 2005). *Enf Infecc Microbiol Clin* 2008; 26: 500-501.
- Deng L, Gui X, Zhang Y, et al. Impact of human immunodeficiency virus infection on the course of hepatitis C virus infection: A meta-analysis. *World J Gastroenterol* 2009; 15: 996-1003
- Graham CS, Baden LR, Yu E, et al. Influence of Human Immunodeficiency Virus Infection on the Course of Hepatitis C Virus Infection: A Meta-Analysis *Clin Infect Dis* 2001; 33: 562-569.
- Kuntzen T, Tural C, Lia B, et al. Intrahepatic mRNA expression in hepatitis C virus and HIV/hepatitis C virus co-infection: infiltrating cells, cytokines, and influence of HAART. *AIDS* 2008; 22: 203-210.
- Lin W, Weinberg EM, Tai AW, et al. HIV increases HCV replication in a TGF- β 1-dependent manner. *Gastroenterology* 2008; 134: 803-811.
- Macías J, Castellano V, Merchante N, et al. Effect of antiretroviral drugs on liver fibrosis in HIV-infected patients with chronic hepatitis C: harmful impact of nevirapine. *AIDS* 2004; 18: 767-774.
- Macías J, Sáez C, Japón MA, et al. Increased hepatocyte Fas expression and apoptosis in human immunodeficiency virus and hepatitis C virus coinfection. *J Infect Dis* 2005; 192: 1566-1576.
- Maida I, Nuñez M, Rios MJ, et al. Severe liver disease associated with prolonged exposure to antiretroviral drugs. *J Acquir Immune Defic Syndr* 2006; 42: 177-182.
- Maida I, Garcia-Gasco P, Sotgiu G, et al. Antiretroviral-associated portal hypertension: a new clinical condition? Prevalence, predictors and outcome. *Antivir Ther* 2008; 13: 103-107.
- Mallet V, Blanchard P, Verkarre V, Vallet-Pichard A, Fontaine H, Lascoux-Combe C, Pol S. Nodular regenerative hyperplasia is a new cause of chronic liver disease in HIV-infected patients. *AIDS* 2007; 21: 187-192.
16. Martín-Carbonero L, Benhamou Y, Puoti M, et al. Incidence and predictors of severe liver fibrosis in human immunodeficiency virus-infected patients with chronic hepatitis C: a European collaborative study. *Clin Infect Dis* 2004; 38: 128-133.
- McGovern B, Ditelberg JS, Taylor LE, et al. Hepatic steatosis is associated with fibrosis, nucleoside analogue use, and hepatitis C virus genotype 3 infection in HIV-seropositive patients. *Clin Infect Dis* 2006; 43: 365-372.
- Merchante N, Girón-González JA, González-Serrano M, et al. Survival and prognostic factors of HIV-infected patients with HCV-related end-stage liver disease. *AIDS* 2006; 20: 49-57.
- Merchante N, Rivero A, de los Santos-Gil I, et al. Insulin resistance is associated with liver stiffness in HIV/HCV-coinfected patients. *Gut* 2009 (in press).
- Moodie EEM, Pai NP, Klein MB. Is Antiretroviral therapy causing long-term liver damage? A comparative analysis of HIV-mono-infected and HIV/hepatitis C co-infected cohorts. *Plos One* 2009; 4: e4517
- Mooser V, Carr A. Antiretroviral therapy-associated hyperlipidaemia in HIV disease. *Curr Opin Lipidol* 2001; 12: 313-319.
- Neau D, Winlock M, Castera L, et al. Prevalence of and factors associated with hepatic steatosis in patients coinfecting with hepatitis C virus and HIV. *J Acquir Immune Defic Syndr* 2007; 45: 168-173.
- Núñez-Fernández C, Martín-Carbonero L, Valencia ME, et al. Liver complications have reached a plateau as cause of hospital admission and death in HIV patients in Madrid. *AIDS Res Hum Retrovir* 2009; 25: 383-385.
- Pascual-Pareja JF, Camino A, Larrauri J, et al. Factors associated with hepatic steatosis in human immunodeficiency virus and hepatitis C virus coinfecting patients. *Med Clin (Barc)* 2009; 132: 208-213.
- Pineda JA, García-García JA, Aguilar-Guisado M, et al. Clinical progression of hepatitis C virus-related chronic liver disease in human immunodeficiency virus-infected patients undergoing highly active antiretroviral therapy. *Hepatology* 2007; 46: 622-630.
- Qurishi N, Kreuzberg C, Luchters G, et al. Effect of antiretroviral therapy on liver-related mortality in patients with HIV and hepatitis C virus coinfection. *Lancet* 2003; 362: 1708-1713.
- Rohrbach J, Harcourt G, Gaudieri S, et al. Successful ART is associated with increasing HCV-specific T cell responses. 16th Conference on Retroviruses and Opportunistic Infections. Montreal (Canada), February 2009. Abstract 105.
- Schiano TD, Kotler DP, Ferran E, Fiel MI. Hepatoportal sclerosis is a cause of noncirrhotic portal hypertension in patients with HIV. *Am J Gastroenterol* 2007; 102: 2536-2540.
- Sulkowski M, Mehta SH, Torbenson M, et al. Hepatic steatosis and antiretroviral drug use among adults coinfecting with HIV and hepatitis C virus. *AIDS* 2005; 19: 585-592.
- Sulkowski M, Mehta SH, Torbenson M, et al. Rapid fibrosis progression among HIV/hepatitis C virus-co-infected adults. *AIDS* 2007; 21: 2209-2216.
- Thein H, Yi Q, Dore GJ, Krahn MD. Natural history of hepatitis C virus infection in HIV-infected individuals and the impact of HIV in the era of highly active antiretroviral therapy: a meta-analysis. *AIDS* 2008; 22: 1979-1991.
- Vergara A, Macías J, Mira JA, et al. Low grade hypertransaminasemia during HAART is not associated with liver fibrosis progression among HIV/HCV-coinfected patients. *J Antimicrob Chemother* 2007; 59: 87-91.
- Verma S, Wang CH, Govindarajan S, Kanel G, Squires K, Bonacini M. Do type and duration of antiretroviral therapy attenuate liver fibrosis in HIV-hepatitis C virus coinfecting patients? *Clin Infect Dis* 2006; 42: 262-270.

Received: December 3, 2009 / Accepted: January 7, 2010

Address for correspondence:

Prof. Juan A. Pineda
 Unidad de Enfermedades Infecciosas
 Hospital Universitario de Valme
 Avda. de Bellavista s/n
 41014 Sevilla
 Spain
 Phone: +34 95/5015684
 Fax: +34 95/5015787
 E-mail: japineda@telefonica.net