

CHURG-STRAUSS SYNDROME: A CASE REPORT

R. M. Mroz, M. Korniluk, E. Swidzinska, E. Chyczewska

Department of Lung Diseases and Tuberculosis, Bialystok Medical University, Bialystok, Bialystok, Poland

Abstract

A fifty-year-old female presented with a one month history of progressive dyspnea, productive cough, pain of elbows and knees, and 40°C fever despite antibiotic treatment. She has been diagnosed of bronchial asthma over 25 years before admission and oral and depot glucocorticosteroids as a long-term therapy was applied. Recently, an attempt of inhaled corticosteroids and LABA treatment was introduced with no success. Four years before admission she also developed peripheral neuropathy. Physical examination revealed tachypnea, wheezes, rhonchi and wet crackles on auscultation, tachycardia, skin nodules, urticarial rash and necrotic bullae all over the body. Chest X-ray showed transient, patchy, nonsegmental areas of consolidation with predilection for lower zones with the area of consolidation in lower left zone. Obstruction was found on spirometry. Tachycardia on ECG and myocardial fluid on ECHO were also detected. Lab exams revealed elevated CRP, WBC, eosinophils, and IgE levels. ANA and ANCA antibodies were not found. Patient was diagnosed of Churg Strauss Syndrome and initial treatment of prednisone was introduced. After four days of treatment, temperature normalized, and dyspnea diminished. After one month of therapy skin lesions regressed. After 18 months of the treatment patient reports no signs, nor symptoms of the disease. Patient continues oral corticosteroid therapy.

Key words: Churg Strauss Syndrome, allergic granulomatosis, ANCA

INTRODUCTION

Churg-Strauss syndrome (CSS) so called allergic granulomatosis is a rare primary, non-inheritable, non-transmissible systemic disease, which typically occurs in patients with a history of bronchial asthma. Peripheral eosinophilia and medium and small vessel autoimmune necrotizing vasculitis, involving multiple organs are the main features of the disease [1]. CSS can be diagnosed by the presence of any four or more of the six criteria, including asthma, eosinophilia greater than 10%, paranasal sinusitis, pulmonary infiltration, histologically confirmed vasculitis and neuropathy [1].

CASE REPORT

A fifty-year-old female presented with a one month history of progressive dyspnea, productive cough, pain of elbows and knees, and 40°C fever despite antibiotic treatment. She had been diagnosed with bronchial asthma over 25 years before admission and oral and depot glucocorticosteroids as a long-term therapy was applied. Recently an attempt of inhaled corticosteroids and LABA treatment was introduced with no success. Four years before admission she also developed peripheral neuropathy. Physical examination revealed tachypnea, wheezes, rhonchi and wet crackles on auscultation, tachycardia, skin nodules, urticarial rash and necrotic bullae all over the body (Table 1, Fig. 1).

Table 1. Principal clinical, radiologic and laboratory features of the case.

Organ/method of detection	Features
Skin	Skin nodules, urticarial rash, necrotic bullae
Lung auscultation	Tachypnea, wheezes, rhonchi, wet crackles
Chest X-ray	Transient, patchy, nonsegmental areas of consolidation with predilection for lower zones with the area of consolidation in lower left zone
ECG/ECHO	Tachycardia /myocardial fluid
Spirometry	FEV ₁
Skin biopsy	Focal, necrotizing vasculitis
Transbronchial lung biopsy	Granulomas, formed by eosynophils with central necrosis, macrophages and giant cells
Sedimentation 1h/2h	90/100
CRP	122 mg/l
WBC	46 x 10 ⁶
Eosynophils	28 x 10 ⁶ - 62%
IgE total	287.4 IU
ANA/ANCA	-/-

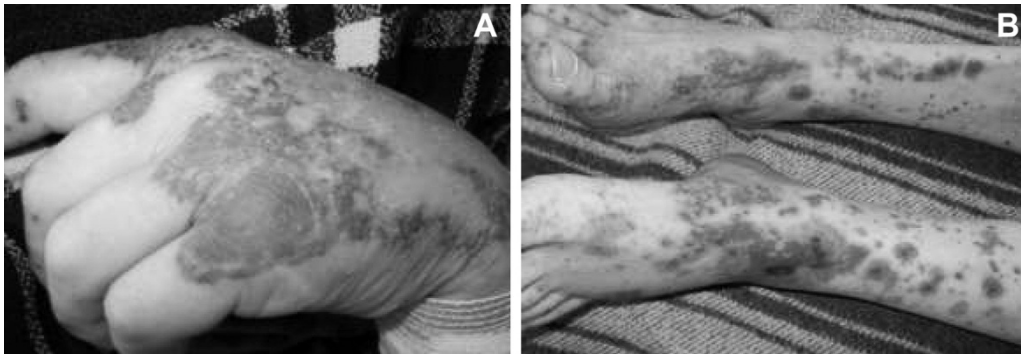

Fig. 1. Skin lesions. Skin nodules, urticarial rash and necrotic bullae (A and B).

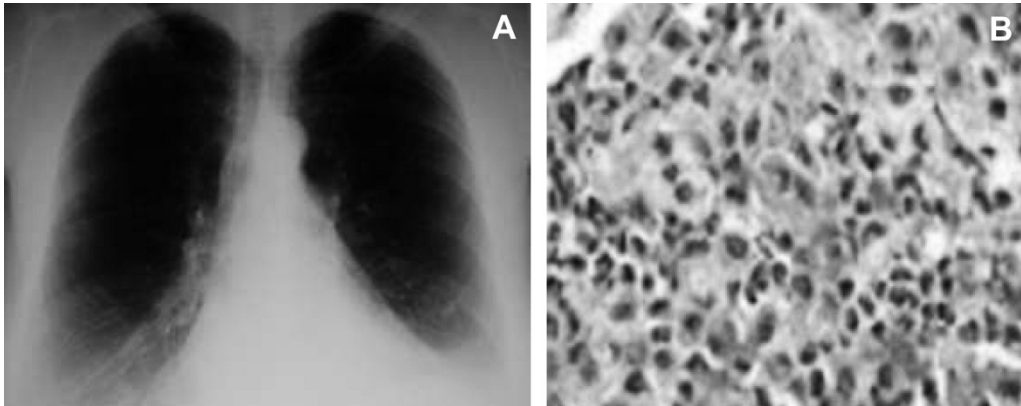


Fig. 2. A - X-ray of the chest: transient, patchy, nonsegmental areas of consolidation with predilection for lower zones with the area of consolidation in lower left zone; B- Transbronchial lung biopsy: granulomas, formed by eosinophils with central necrosis, macrophages and giant cells.

Chest X-ray showed transient, patchy, nonsegmental areas of consolidation, with predilection for lower zones with the area of consolidation in lower left zone (Table 1, Fig. 2A). Tachycardia on ECG and myocardial fluid on ECHO were also found. Obstruction was found on spirometry. Skin biopsy revealed focal, necrotizing vasculitis. Transbronchial lung biopsy revealed granulomas, formed by eosinophils with central necrosis, macrophages and giant cells (Table 1, Fig. 2B). Lab exams revealed elevated CRP, WBC, eosinophils and IgE levels. ANA and ANCA antibodies were not found.

Patient was diagnosed with Churg Strauss Syndrome and initial treatment with prednisone was introduced at a dose of 60 mg per day, i.e. 1 mg/kg/day. After four days of treatment, temperature normalized, and dyspnea diminished. After one month of therapy, skin lesions regressed. Then, prednisone dose was titrated according to the level of blood eosinophils. After 18 months of treatment, the patient reported no signs or symptoms of the disease. Patient continues oral corticosteroid therapy at a dose of 10 mg of prednisone per day.

DISCUSSION

Idiopathic primary systemic vasculitides are defined, according to the Chapel Hill Consensus Conference [2], on the basis of the size of vessels involved, clinical symptoms, and histopathological features. According to the American College of Rheumatology (ACR), classification criteria of the CSS are: small vessel vasculitis along with Wegener's granulomatosis (WG), microscopic polyangiitis (MPA), and idiopathic necrotizing crescentic glomerulonephritis NCGN [3]. Al-

though, CSS can affect any organ system in the body, lung blood vessels involvement is one of the main features of the disease. Asthma, peripheral eosinophilia, peripheral neuropathy, pulmonary infiltrates, and paranasal sinus abnormalities remain the major classification criteria of the disease [1].

Our patient had been diagnosed with bronchial asthma over 25 years before admission. Skin lesions are the most common extra-pulmonary findings in the course of the disease. The main types of skin lesions reported include erythematous maculopapules resembling erythema multiforme, hemorrhagic lesions ranging from petechiae to extensive ecchymosis, often associated with wheals, necrosis and ulceration, and cutaneous and subcutaneous nodules that are usually deep-seated and tender with a predilection for the scalp and temple region. Others report livedo reticularis, papulovesicles, non-pitting periorbital edema, and nail-fold infarcts [4-8]. Skin nodules urticarial rash and necrotic bullae all over the body were found in our patient. Regarding clinical features, our patient complained of progressive dyspnea, productive cough, pain of elbows and knees, and 40°C fever, despite the antibiotic and steroid treatment. We also found radiologic changes, such as pulmonary infiltrates detected by X-ray and computed tomography, and other manifestations including, mononeuritis multiplex, eosinophilic endomyocarditis, with no renal involvement documented. These are consistent with main clinical findings describing the disease [1, 3-5]. We did not find positive antineutrophil cytoplasmic antibodies (ANCA) in our patient. According to Reid et al [9] and Della Rosa et al [10] positive ANCA may be found in 39 to 59% of patients with CSS. Sable-Fourtassou et al [11] found the predominance of glomerulonephritis

and peripheral neuropathy among positive ANCA patients, and more frequent cardiac involvement, and fever, among ANCA negative patients. Based on that, these authors hypothesized that ANCA positivity may reflect an active vasculitic process, while ANCA negativity may be more frequently linked to another clinical phenotype that could correspond to different pathogenic mechanisms which are less often associated with ANCA. Consistently with their hypothesis, cardiac involvement and no glomerulonephritis characterized our case, with the exception for peripheral neuropathy presented. According to Sable-Fourtassou et al [11] a higher frequency of vasculitis in biopsy specimens from the ANCA-positive group and a close association of renal involvement with ANCA positivity support a pathogenic role for ANCA. Kallenberg et al [12] focusing on ANCA directed to proteinase-3 (PR3-ANCA) or myeloperoxidase (MPO-ANCA) summarized that ANCA alone are not sufficient, as based on clinical and experimental data, and other, probably exogenous factors, seem necessary for disease induction and (re)activation. In particular, silica, the carriage of *Staphylococcus aureus*, and various genetic factors may underline susceptibility to the disease. We did not find any bacterial source of infection or any genetic factors in our patient. Concerning treatment, our patient received a conventional prednisone therapy, resulting in early regression of clinical features. Further dose of the drug was titrated according to the level of blood eosinophils, with no signs or symptoms of the disease during a follow-up of 18 months of therapy. Despite novel therapies being introduced, systemic corticosteroids are still considered the cornerstone treatment [13]. Swietlik and Doboszynska [14] suggest the use of inhaled corticosteroids as a recurrence preventing approach and this may be a further step to be taken in our patient. Lamprecht et al [15] in their most recent publication summarize that anti-CD20 therapy and TNF-alpha-antagonists may represent strategies for refractory disease, but evidence from controlled trials is still lacking [15].

Conflicts of interest: The authors had no conflicts of interest to declare in relation to this article.

REFERENCES

- Churg J, Strauss L. Allergic granulomatosis, allergic angiitis and periarteritis nodosa. *Am J Pathol* 1951; 27: 277-301.
- Jennette JC, Falk RJ, Andrassy K, Bacon PA, Churg J, Gross WL, Hagen EC, Hoffman GS, Hunder GG, Kallenberg CG, McCluskey RT, Sinico RA, Rees AJ, van Es LA, Waldherr R, Wilk A. Nomenclature of systemic vasculitides: the proposal of an international consensus conference. *Arthritis Rheum* 1994; 37(2): 187-92.
- Fries JF, Hunder GG, Bloch DA, Michel BA, Arend WP, Calabrese LH, Fauci AS, Leavitt RY, Lie JT, Lightfoot RW Jr, Masi AT, McShane DJ, Mills JA, Stevens MB, Wallace SL, Zvaifler NJ. The American College of Rheumatology 1990 criteria for the classification of vasculitis. Summary. *Arthritis Rheum* 1990; 33(8): 1135-6.
- Lanham JG, Elkon KB, Pusey CD, Hughes GR. Systemic vasculitis with asthma and eosinophilia: A clinical approach to the Churg-Strauss syndrome. *Medicine (Baltimore)* 1984; 63: 65-81.
- Guillevin L, Cohen P, Gayraud M, Lhote F, Jarrousse B, Casassus P. Churg-Strauss syndrome. Clinical study and long-term follow-up of 96 patients. *Medicine (Baltimore)* 1999; 78: 26-37.
- Kawakami T, Soma Y, Kawasaki K, Kawase A, Mizoguchi M. Initial cutaneous manifestations consistent with mononeuropathy multiplex in Churg-Strauss syndrome. *Arch Dermatol* 2005; 141: 873-8.
- Davis MD, Daoud MS, McEvoy MT, Su WP. Cutaneous manifestations of Churg-Strauss syndrome: A clinicopathologic correlation. *J Am Acad Dermatol* 1997; 37: 199-203.
- Choi JH, Ahn IS, Lee HB, Park CW, Lee CH, Ahn HK. Case of Churg-Strauss Syndrome. *Ann Dermatol* 2009; 21(2): 213-6.
- Reid AJ, Harrison BD, Watts RA, Watkin SW, McCann BG, Scott DG. Churg-Strauss syndrome in a district hospital. *QJM* 1998; 91: 219-29.
- Della Rossa A, Baldini C, Tavoni A, Tognetti A, Neglia D, Sambucetti G, Puccini R, Colangelo C, Bombardieri S. Churg-Strauss syndrome: Clinical and serological features of 19 patients from a single Italian centre. *Rheumatology (Oxford)* 2002; 41: 1286-94.
- Sable-Fourtassou R, Cohen P, Mahr A, Pagnoux C, Mouthon L, Jayne D, Blockmans D, Cordier J-F, Delaval P, Puechal X, Lauque D, Viallard J-F, Zoulim A, Guillevin L, and the French Vasculitis Study Group. Antineutrophil cytoplasmic antibodies and the Churg-Strauss Syndrome. *Ann Intern Med* 2005; 143: 632-8.
- Kallenberg CG, Rarok A, Stegeman CA, Limburg PC. New insights into the pathogenesis of antineutrophil cytoplasmic autoantibody-associated vasculitis. *Autoimmun Rev* 2002; 1: 61-6.
- Baldini C, Talarico R, Della Rossa A, Bombardieri S. Clinical Manifestations and Treatment of Churg-Strauss Syndrome. *Rheum Dis Clin North Am* 2010; 36(3): 527-43.
- Swietlik E, Doboszynska A. Treatment of Churg-Strauss syndrome with an inhaled corticosteroid after oral steroids discontinuation due to side effects. *J Physiol Pharmacol* 2008; 59 Suppl 6: 689-95.
- Lamprecht P, Holle J, Gross WL. Update on clinical, pathophysiological and therapeutic aspects in ANCA-associated vasculitides. *Curr Drug Discov Technol* 2009; 6(4): 241-51.

Address for correspondence:

Robert M. Mroz
 Department of Lung Diseases and Tuberculosis
 Medical University of Bialystok
 14, Zurawia St.
 15-540 Bialystok
 Poland
 Phone: +48 85 7409530
 Fax: +48 85 6545419
 E-mail: robmroz@wp.pl