

CASE REPORT

Open Access



# Gouty tophus as a rare cause of a Hepple stage V osteochondral lesion of the talus

Bo Tang and Cheng Fan\*

## Abstract

**Background:** Talus osteochondral lesion is commonly associated with trauma, avascular necrosis or even genetic factors, but gouty tophus as a cause of Hepple stage V type talus osteochondral lesion is rare.

**Case presentation:** Here, we report a case of an 18-year-old man who complained of left medial deep ankle pain on ambulation. This young man had an extreme liking of sea food rich in purines and also sugar-sweetened drinks. He was diagnosed with a Hepple stage V type talus osteochondral lesion and was treated with medial malleolus osteotomy and an osteochondral graft. The talus osteochondral lesion was found to be a gouty tophus and was completely removed. Hypouricemic therapy was prescribed for 2 months, which allowed the patient to walk with a visual analogue score (VAS) score of 1. He was followed up for 12 months.

**Conclusions:** Young people with an extreme liking of sea food rich in purines and also sugar-sweetened drinks may be at a risk of developing gout. Acute onset of ankle atraumatic pain, swelling with a high level of serum uric acid and a talus osteochondral lesion with cyst formation should make physicians consider a diagnosis of gout.

**Keywords:** Gout, Talus osteochondral lesion, Diet, Young patient, Treatment

## Background

Talus osteochondral lesion is characterized by damage to the articular cartilage of the talus and its underlying subchondral bone and can result in persistent ankle pain or osteoarthritis [1]. If conservative therapy such as non-steroidal anti-inflammatory drugs, hyaluronic acid or platelet-rich plasma injection, or limited weight-bearing failed, surgical intervention mainly including arthroscopic debridement, microfracture, osteochondral autologous or allograft transplantation is the treatment of choice [2]. The Hepple classification has been widely used for the diagnosis and treatment of talus osteochondral lesion. Combination therapy of arthroscopic debridement or microfracture, and hyaluronic acid or platelet-rich plasma injection are mainly used for I to IV type lesions, and osteochondral grafts are often required to manage

satisfactorily a Hepple stage V type lesion, which refers to subchondral cyst formation [3]. Talus osteochondral lesions have been reported to be commonly correlated with foot and ankle trauma, avascular necrosis or genetic factors [2], but gouty tophus as a cause of a Hepple stage V type talus osteochondral lesion is rare. Historically, gout was commonly seen in the aged population, with few young people suffering from this condition. Here, we report an 18-year-old male patient with a severe Hepple stage V type talus osteochondral lesion caused by a gout tophus that was successfully treated with an autologous graft and hypouricemic therapy combined with diet modification.

## Case presentation

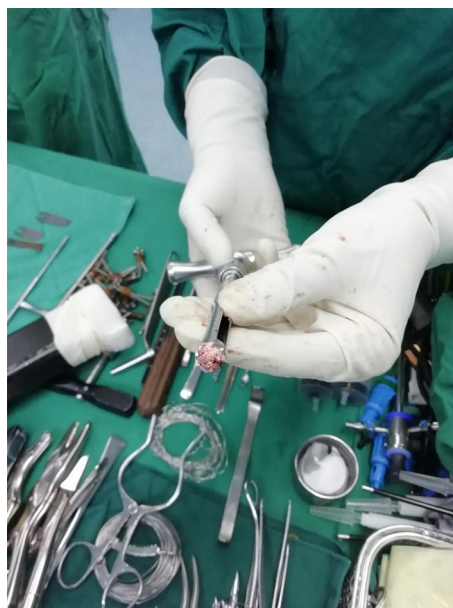A 172-cm tall, 18-year-old man, weight 100 kg, was admitted to our department in January 2020 due to left medial deep ankle pain after stamping the clutch about 10 days ago, who had an extreme liking of seafood, beer and carbonated drinks. During the physical examination,

\*Correspondence: fancheng198454@126.com  
Sports Medicine Center, First People's Hospital of Xining City,  
Xining 810000, Qinghai, China



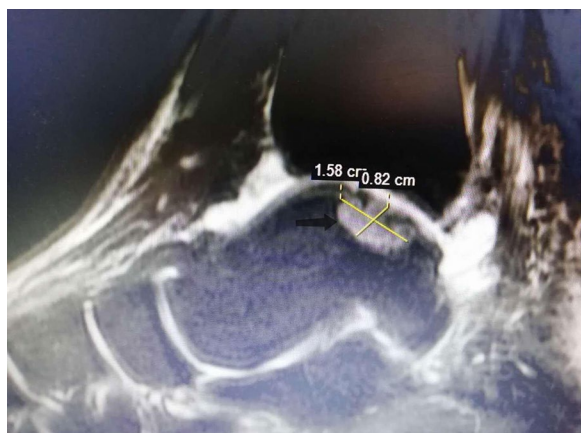
© The Author(s) 2021. **Open Access** This article is licensed under a Creative Commons Attribution 4.0 International License, which permits use, sharing, adaptation, distribution and reproduction in any medium or format, as long as you give appropriate credit to the original author(s) and the source, provide a link to the Creative Commons licence, and indicate if changes were made. The images or other third party material in this article are included in the article's Creative Commons licence, unless indicated otherwise in a credit line to the material. If material is not included in the article's Creative Commons licence and your intended use is not permitted by statutory regulation or exceeds the permitted use, you will need to obtain permission directly from the copyright holder. To view a copy of this licence, visit <http://creativecommons.org/licenses/by/4.0/>. The Creative Commons Public Domain Dedication waiver (<http://creativecommons.org/publicdomain/zero/1.0/>) applies to the data made available in this article, unless otherwise stated in a credit line to the data.

medial ankle tenderness and mild swelling were present, with a VAS score of 6 or 7, but the range of ankle motion was normal. Ankle X-rays, computerized tomography (CT) and magnetic resonance imaging (MRI) scans were conducted and a medial talus osteochondral lesion with subchondral cyst formation was detected (Fig. 1). Various laboratory tests detected high levels of uric acid (568  $\mu\text{mol/L}$ ), anti-streptolysin O (130.10 IU/mL), procalcitonin (0.28 ng/mL) and a high level of serum C-reactive protein (39.50 mg/L). The patient's erythrocyte sedimentation rate, blood cell counts, and other biochemical indexes were all within the normal range. He was primarily diagnosed with a Hepple stage V type talus osteochondral lesion, but the etiology was not clear. An ankle arthroscopy was conducted, and we found a few gouty tophus deposits in the talus articular cartilage and synovial tissue. The medial, central talus articular cartilage was soft, uneven and partially defective, with gouty tophus deposits. A 1.5-mm K-wire was drilled into this site to confirm the talus lesion site under C-arm fluoroscopy. A medial curved incision was made on the medial malleolus and the talus osteochondral lesion was exposed after inverted V-shaped medial malleolus osteotomy and removed with trephine; the removed lesions were found to be gouty tophus (Fig. 2), which was further confirmed by the finding of monosodium urate monohydrate (MSU) crystals in postoperative histological sections (Fig. 3). After complete debridement of these lesions, the lesion site was not a regular shape, and a very small amount of normal osteochondral tissue was cut with a small osteotome to form a square lesion site. Then an osteochondral block of the same size was harvested from the autologous talus neck and grafted onto the site and fixed with two 2.0 mm bioabsorbable screws. The donor site was filled

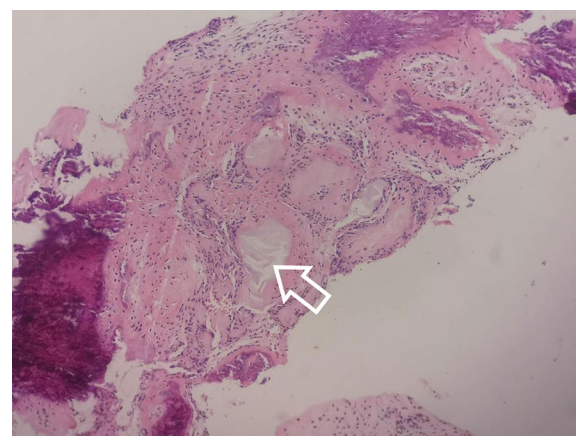


**Fig. 2** The talus osteochondral lesion was removed with trephine. White gouty tophus removed with a trephine was found during the operation

and tamped with the cancellous bone on the osteotomy surface of the medial malleolus. Then the medial malleolus was fixed with three cannulated screws after reduction. Aceclofenac dispersible tablets and allopurinol were taken by the patient immediately after the operation and he was advised to use his left ankle passively, with no weight-bearing for 5 weeks. At this time his serum uric acid concentration was in the normal range and a good



**Fig. 1** Ankle MRI of the 18-year-old young male patient. T2-weighted sagittal view of the ankle MRI revealed a  $0.94 \times 0.82 \times 1.58$  cm, well-defined, cystic structure in medial, central talus (arrow)



**Fig. 3** Postoperative histological results of the removed lesions. Monosodium urate monohydrate (MSU) crystals (white arrow) were found in postoperative hematoxylin and eosin-stained histological sections

medial malleolus union was revealed by X-ray imaging. Partial weight-bearing was encouraged 2 months post-operatively when the cyst talus osteochondral lesion had disappeared and was replaced with normal bone tissue 6 months postoperatively. The patient could walk with slight pain at this time with a VAS score of 1 and was very satisfied with the outcome. Regular monitoring of serum uric acid concentrations and his modified diet continued, and he has been followed up for 12 months.

## Discussion

The Hepple stage V type talus osteochondral lesion was mainly managed using an osteochondral grafting technique, with positive results having been reported in several previous studies [4, 5]. It is noteworthy, however, that this case of a Hepple stage V type talus osteochondral lesion was caused by gout tophus. An osteochondral graft harvested from the autologous talus neck combined with hypouricemic therapy and diet modification produced a satisfactory clinical outcome.

It has been reported that gout is commonly diagnosed in patients aged >60 years of age [6]. The present case was an 18-year-old male with a severe talus osteochondral lesion caused by gout tophus, which may have developed due to his bad dietary habit; he told us that he had an extreme liking for seafood, beer and carbonated drinks, all known risk factors for gout [7, 8]. In the literature, we found a similar report on gout tophus as an unusual cause of talus fracture, but this was a 41-year-old man with a 20-year history of untreated gout, and pathological talus fracture-like neoplastic bone destruction was also reported [9], whereas in the present case the cyst lesion was well defined. We also found a remarkably similar report on gout tophus as an unusual cause of talus osteochondral lesion in a 16-year-old male who complained of fluctuating ankle pain on the anteromedial side, which was successfully managed with arthroscopic debridement and microfracture [10]. In the present case, osteochondral autologous transplantation was employed mainly due to the relatively larger lesion size. A systematic review has suggested that microfracture may best be reserved for lesion sizes less than 107.4 mm<sup>2</sup> in area and/or 10.2 mm in diameter [11]. However, a recent review also indicated that no consensus has been reached regarding the treatment of osteochondral lesions of the talus due to limited high-level evidence [12].

In addition, the question remains why this patient did not suffer a gout flare previously when the severe talus osteochondral lesion had occurred, and why the gout tophus was concentrated on the talus subchondral region. It should be mentioned that during his operation gout tophus was found to be deposited on the ankle synovial and talus articular cartilage. Further research

will be required to clarify the underlying etiology of a severe, localized talus osteochondral lesion caused by gout tophus. Nevertheless, we present this case to raise attention to the previous diet of this young man which was rich in purines, and also his excessive consumption of beer and sugar-sweetened carbonated drinks. This was the probable reason for the development of the severe talus osteochondral lesion in this patient at such a young age.

## Conclusions

Although gout is mainly diagnosed in the aged population, young people who like extreme diets that include sea food rich in purines, beer and sugar-sweetened carbonated drinks may be at risk of prematurely developing gout.

A severe talus osteochondral lesion occurred in our young patient without previous gout flares. An acute onset of ankle atraumatic pain, swelling with a high concentration of serum uric acid and a talus osteochondral lesion with cyst formation should make a physician think of gout as the diagnosis.

A Hepple stage V type talus osteochondral lesion due to gouty tophus can be successfully managed with an autologous osteochondral graft combined with uric acid-lowering therapy and diet modification.

## Abbreviations

VAS: Visual analogue score; MSU: Monosodium urate monohydrate; CT: Computerized tomography; MRI: Magnetic resonance imaging.

## Acknowledgements

This research did not receive any specific grant from any funding agency in the public, commercial, or not-for-profit sector.

## Authors' contributions

BT was responsible for the conception and design of the study. BT was also responsible for data analysis and drafting the manuscript. CF revised and commented on the draft. Both authors have read and approved the final manuscript.

## Funding

Not applicable.

## Availability of data and materials

Data sharing not applicable to this article as no datasets were generated or analyzed during the current study.

## Declarations

### Ethics approval and consent to participate

This study was approved by the institutional research ethics committee of Xining First People's Hospital, and written informed consent was obtained from the patient.

### Consent for publication

Written informed consent was obtained from the patient for publication of this case report and accompanying images.

**Competing interests**

The authors declare that they have no competing interests.

Received: 20 April 2021 Accepted: 5 October 2021

Published online: 19 October 2021

**References**

- Guimarães JB, da Cruz IAN, Nery C, et al. Osteochondral lesions of the talar dome: an up-to-date approach to multimodality imaging and surgical techniques. *Skeletal Radiol*. 2021. <https://doi.org/10.1007/s00256-021-03823-7>.
- Rikken QGH, Kerkhoffs GMMJ. Osteochondral lesions of the talus: an individualized treatment paradigm from the amsterdam perspective. *Foot Ankle Clin*. 2021;26(1):121–36.
- Li S, Lu R, Zhang J, et al. Outcomes of arthroscopic bone graft transplantation for Hepple stage V osteochondral lesions of the talus. *Ann Transl Med*. 2021;9(10):884.
- Zhang L, Luo Y, Zhou X, et al. Outcomes from Osteochondral Autograft Transplant or Mosaicplasty in 26 Patients with Type V Osteochondral Lesions of the Talus. *Med Sci Monit*. 2021;27: e930527.
- Nguyen A, Ramasamy A, Walsh M, et al. Autologous osteochondral transplantation for large osteochondral lesions of the talus is a viable option in an athletic population. *Am J Sports Med*. 2019;47(14):3429–35.
- Abhishek A. Managing gout flares in the elderly: practical considerations. *Drugs Aging*. 2017;34:873–80.
- Kuo CF, Grainge MJ, Zhang W, et al. Global epidemiology of gout: prevalence, incidence and risk factors. *Nat Rev Rheumatol*. 2015;11:649–62.
- Choi HK, Atkinson K, Karlson EW, Willett W, Curhan G. Purine-rich foods, dairy and protein intake, and the risk of gout in men. *N Engl J Med*. 2004;350:1093–103.
- Thomson S, Urbanski S, MacMullan P. Clinical images: gouty tophus as an unusual cause of talus fracture. *Arthritis Rheumatol*. 2017;69(7):1508.
- Kim T, Choi Y-R. Osteochondral lesion of talus with gout tophi deposition: a case report. *World J Clin Cases*. 2020;8(17):3814–20.
- Ramponi L, Yasui Y, Murawski C, et al. Lesion size is a predictor of clinical outcomes after bone marrow stimulation for osteochondral lesions of the talus: a systematic review. *Am J Sports Med*. 2017;45(7):1698–705.
- Qulaghassi M, Cho YS, Khwaja M, et al. Treatment strategies for osteochondral lesions of the talus: a review of the recent evidence. *Foot*. 2021;47: 101805.

**Publisher's Note**

Springer Nature remains neutral with regard to jurisdictional claims in published maps and institutional affiliations.

Ready to submit your research? Choose BMC and benefit from:

- fast, convenient online submission
- thorough peer review by experienced researchers in your field
- rapid publication on acceptance
- support for research data, including large and complex data types
- gold Open Access which fosters wider collaboration and increased citations
- maximum visibility for your research: over 100M website views per year

At BMC, research is always in progress.

Learn more [biomedcentral.com/submissions](https://biomedcentral.com/submissions)

